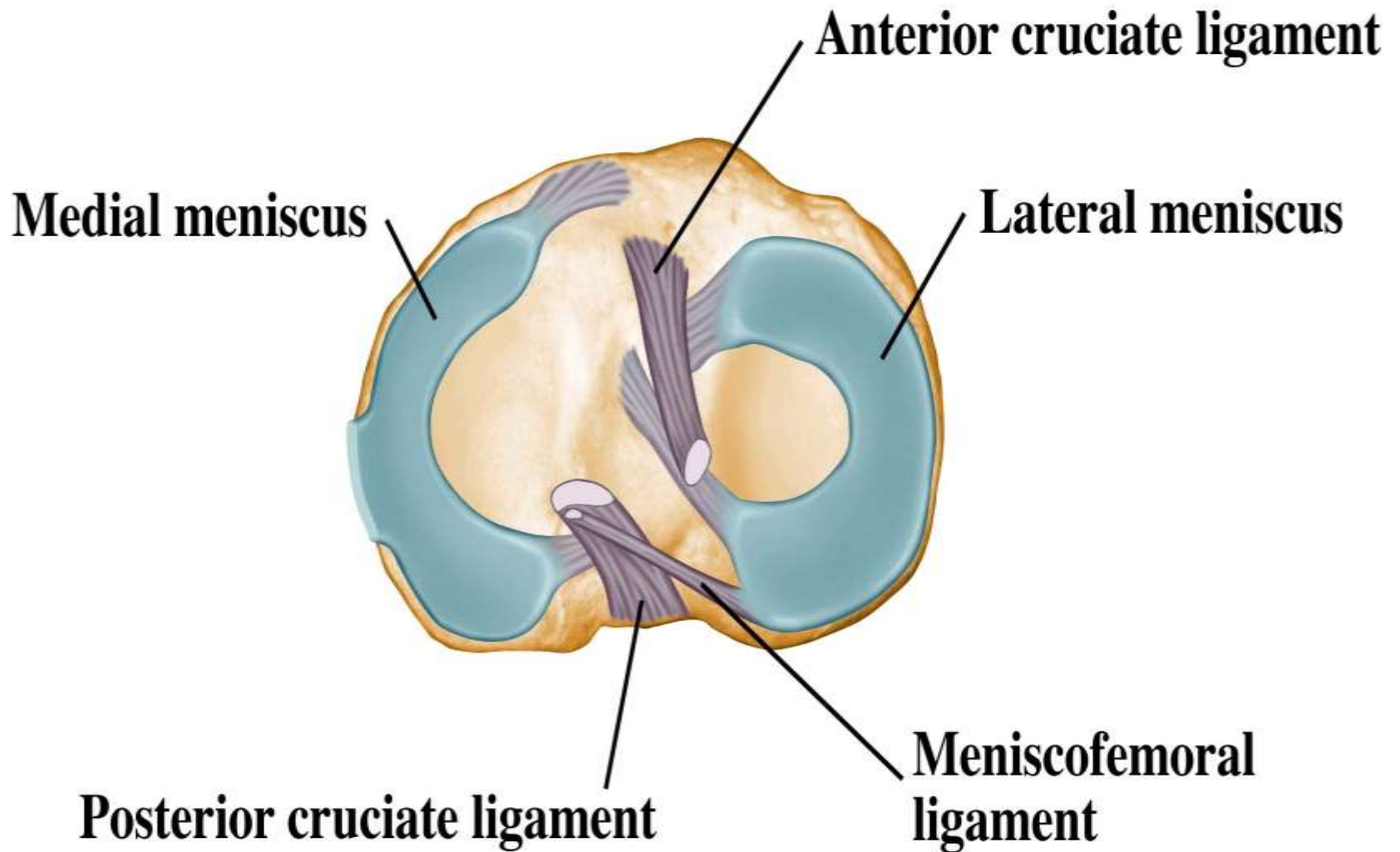


Upper Leg and Knee

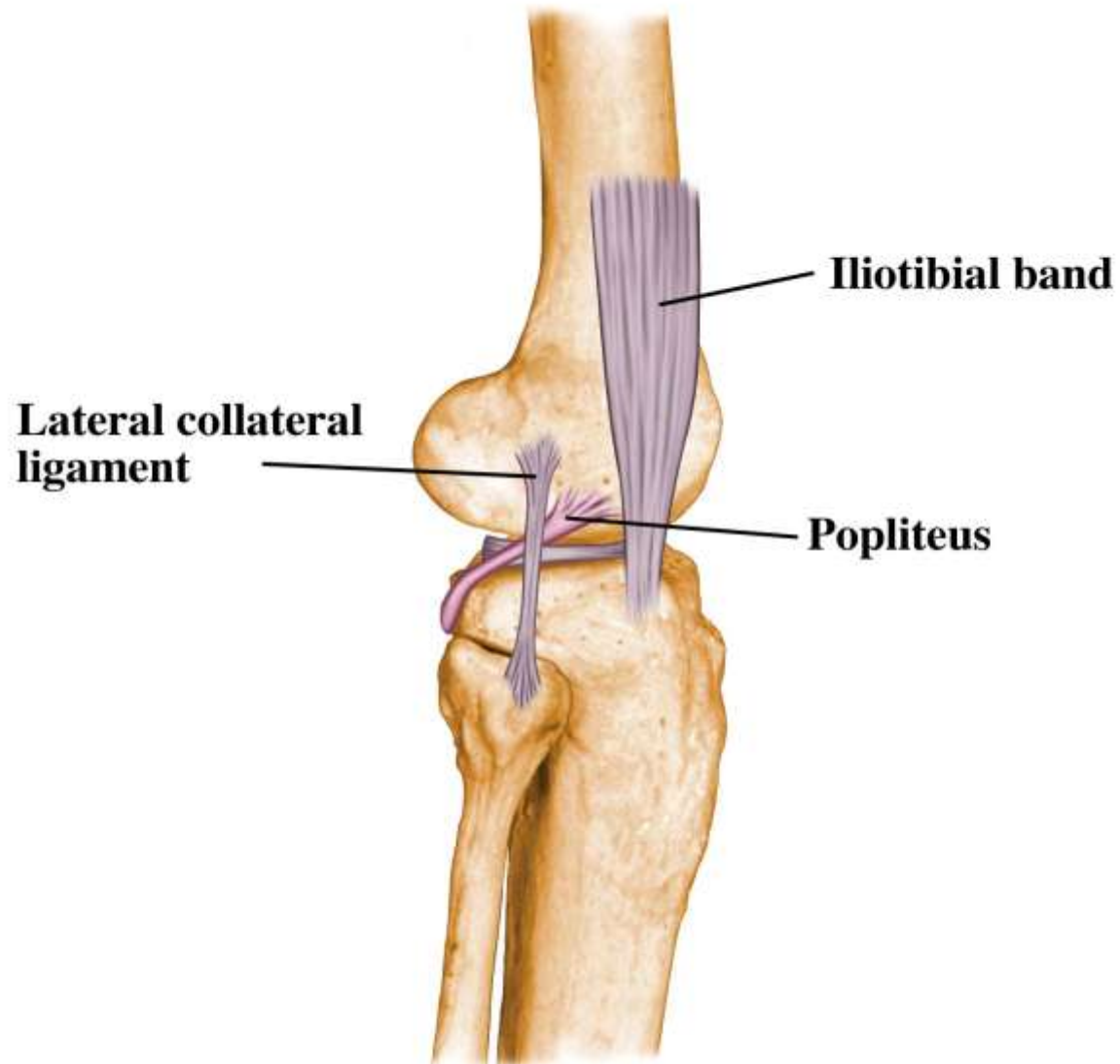


Joint



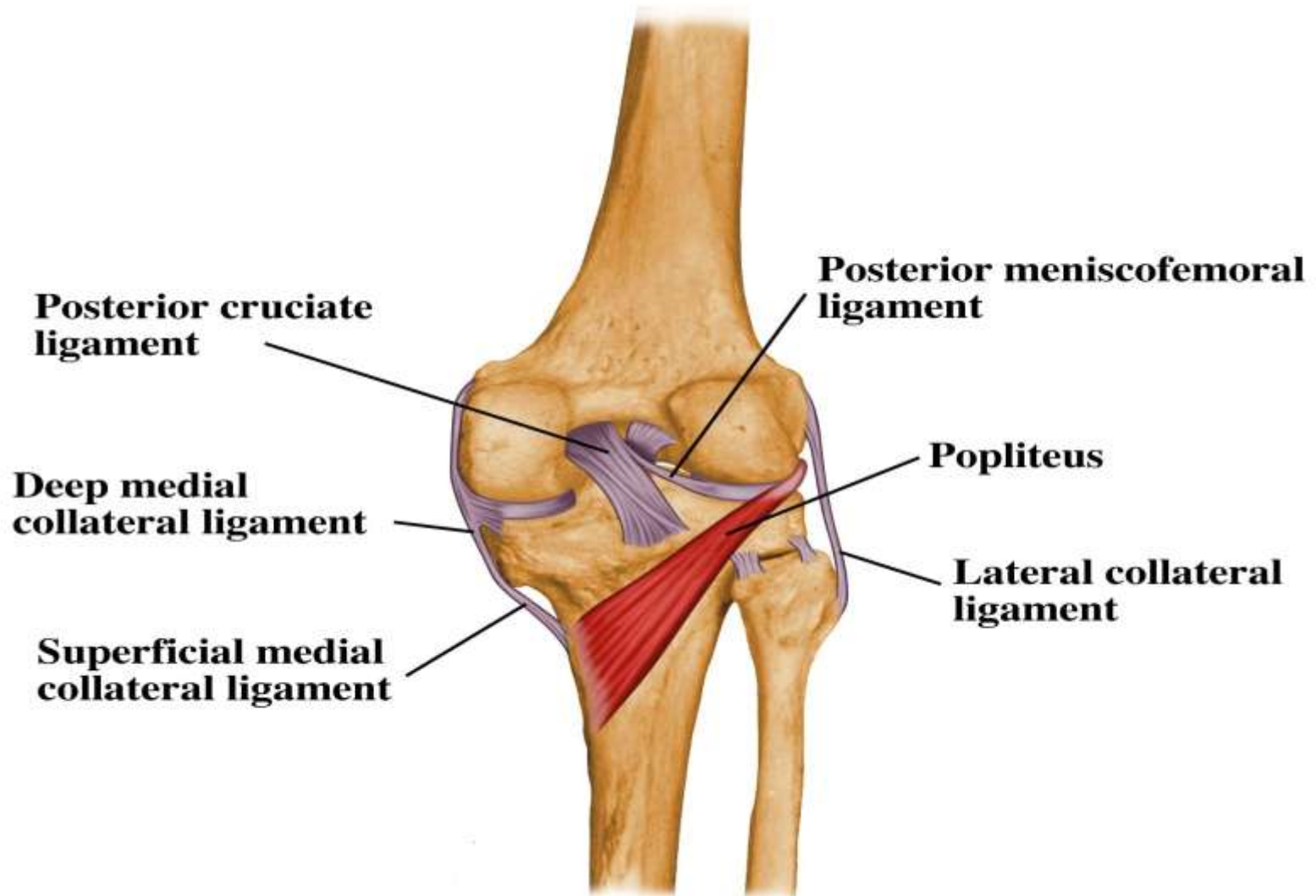


Joint



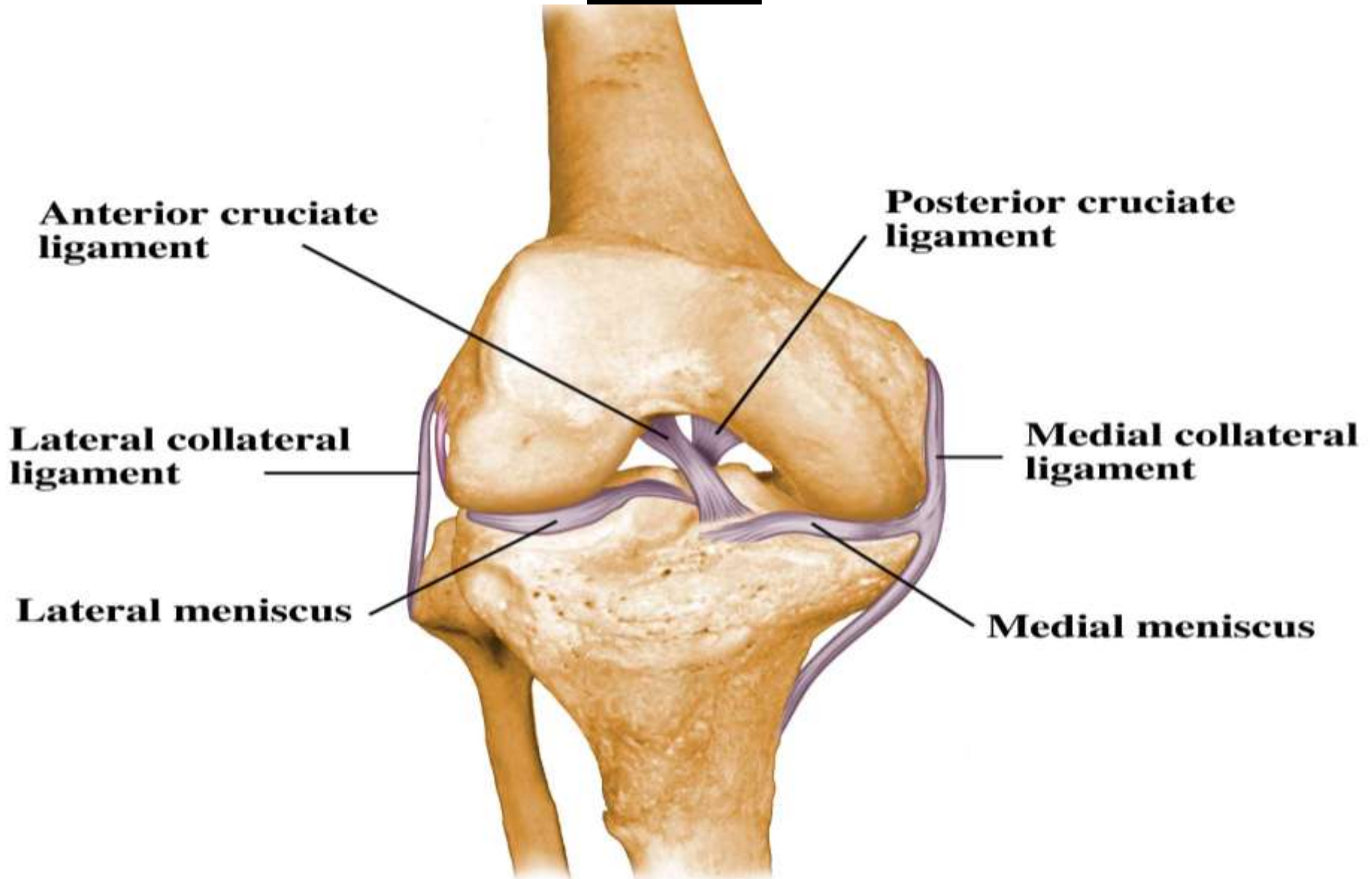


Joint



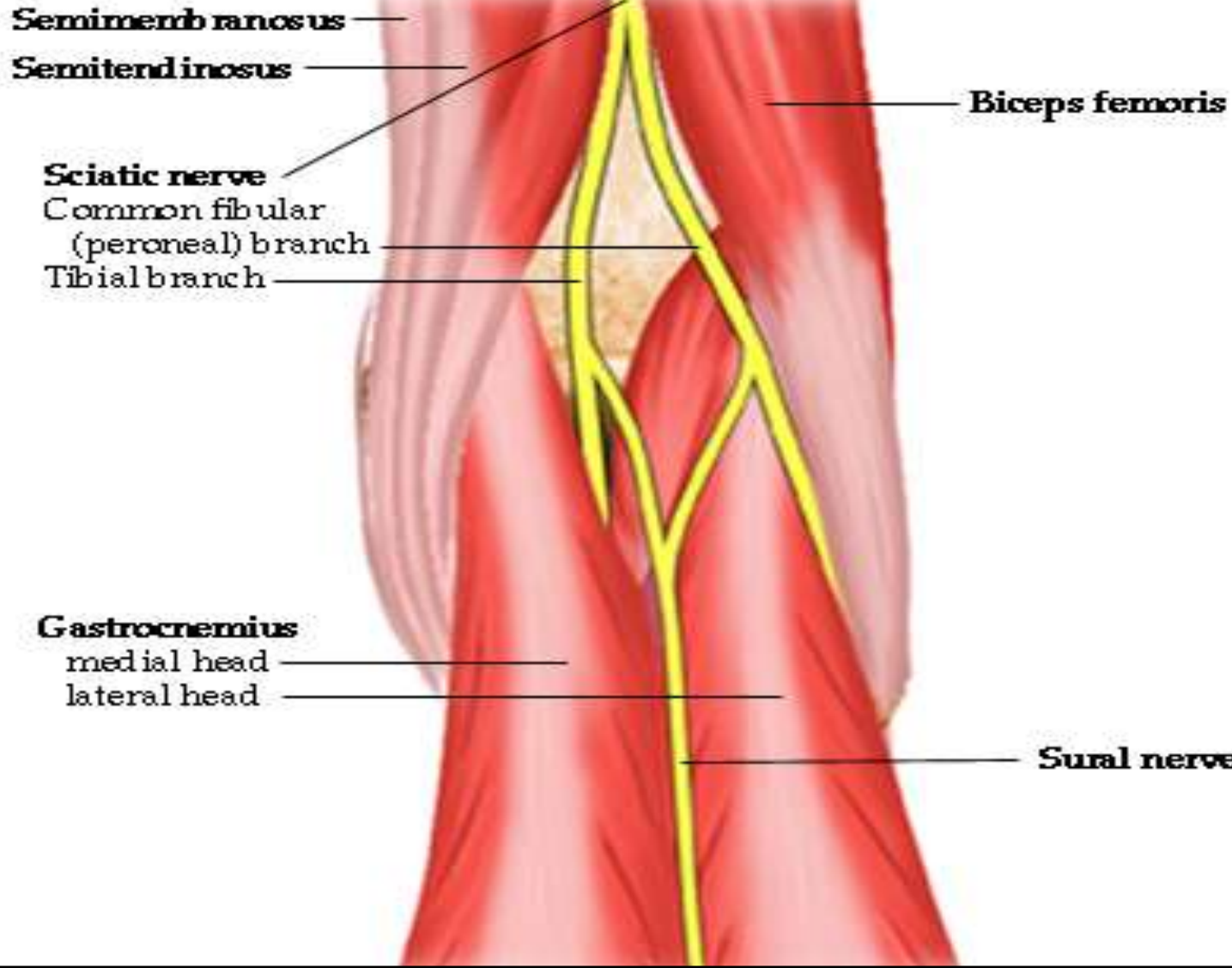


Joint





Sciatic Nerve



Medial Hamstrings

Actions

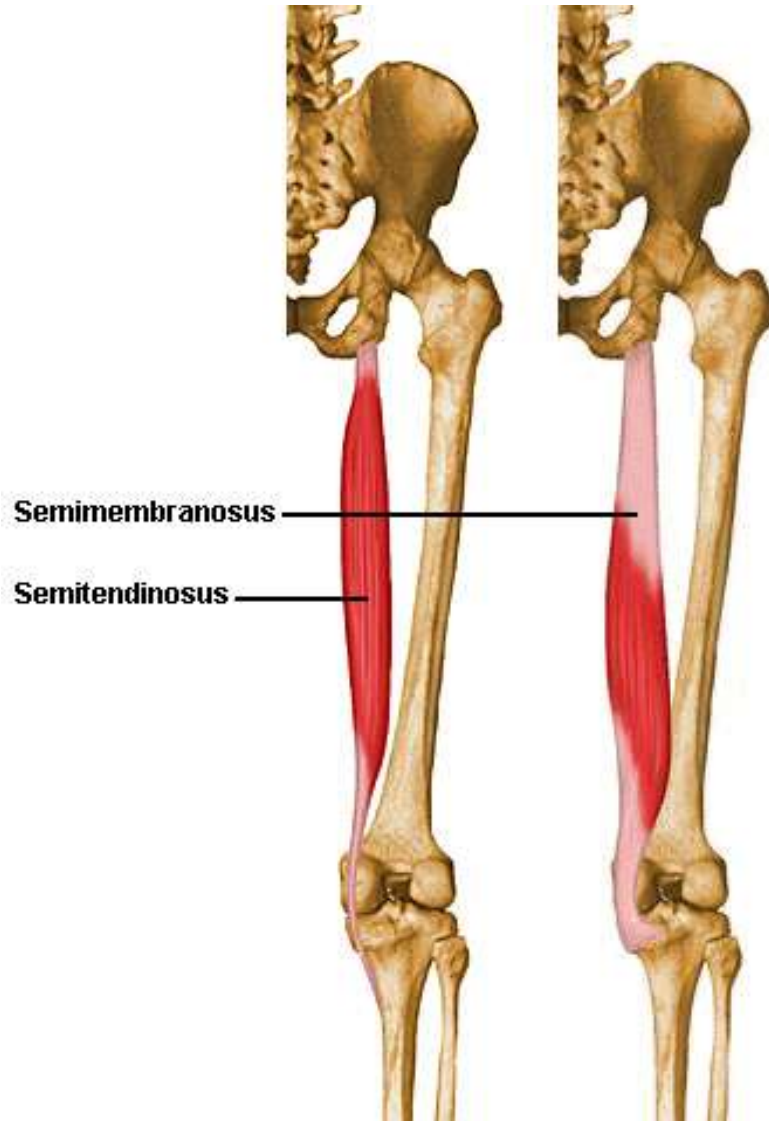
Both: flexes knee; extends hip

Origins

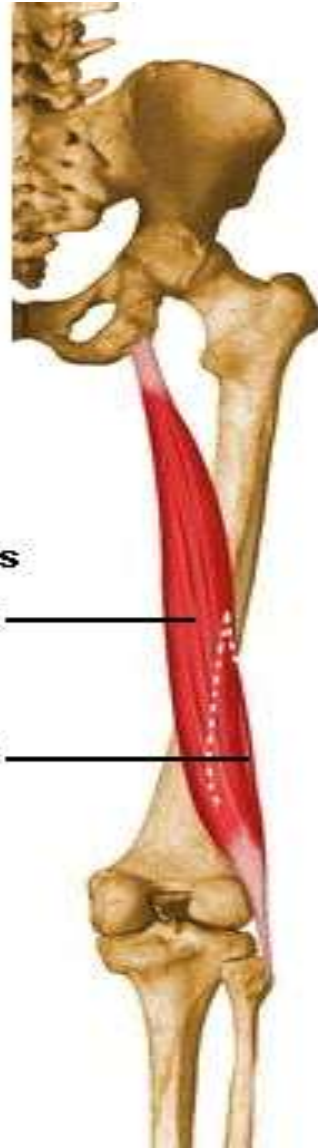
Both: ischial tuberosity

Insertions

Semitendinosus: Upper anterior medial surface of tibia
Semimembranosus: Posteromedial surface of medial tibial condyle



Biceps Femoris



Biceps femoris

long head

short head

Actions

Flexes Knee; extends hip

Origins

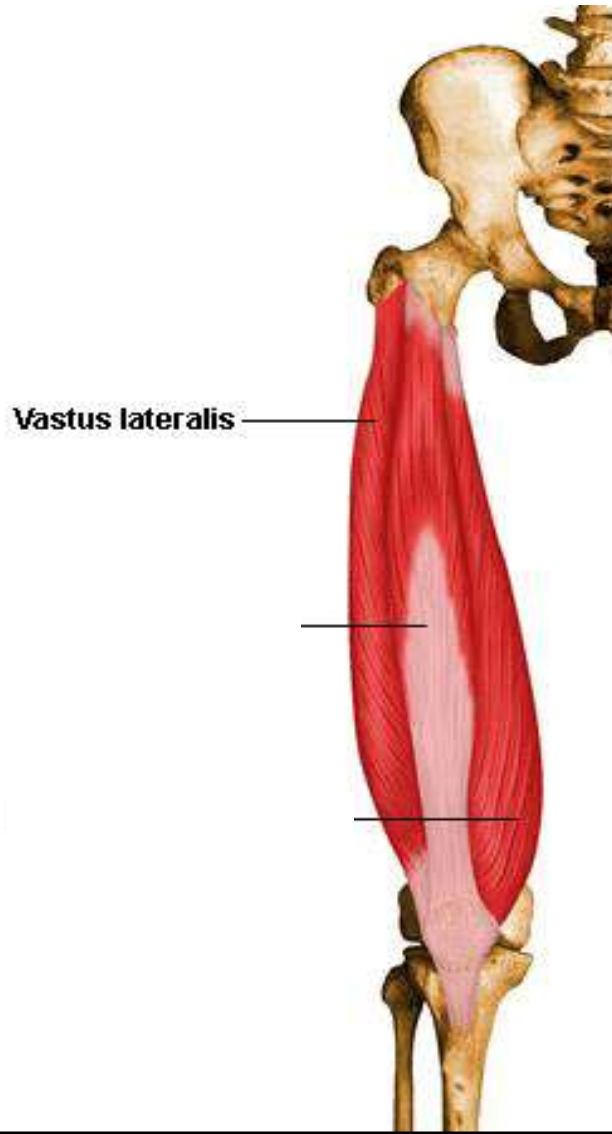
Long head: ischial tuberosity

Short head: lower half of linea aspera,
and lateral condyloid ridge

Insertions

Lateral condyle of tibia and head of
fibula

Vastus Lateralis



Actions

Extends knee

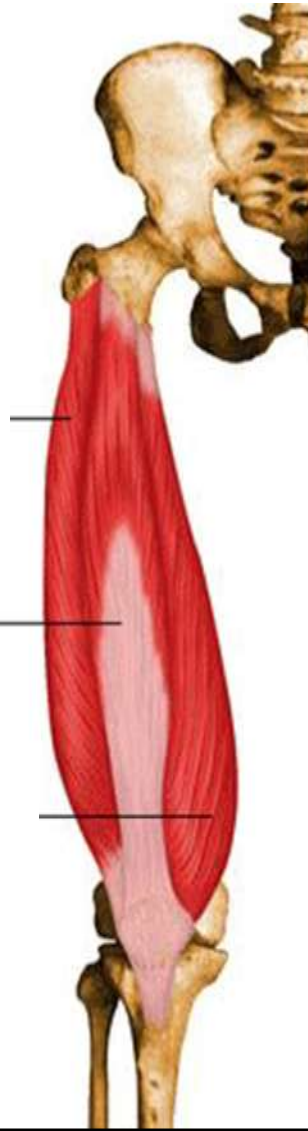
Origins

Anterior and inferior borders of greater trochanter, gluteal tuberosity, upper half of linea aspera and entire lateral intermuscular septum

Insertions

Lateral border of patella and patella tendon to tibial tuberosity

Vastus Intermedius



Actions

Extends the knee

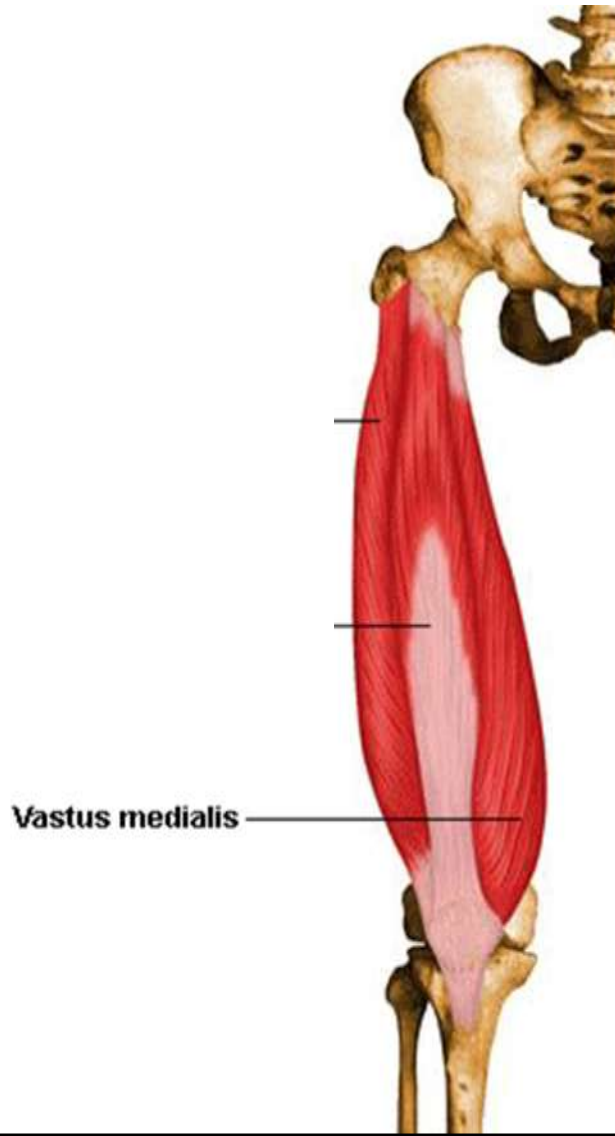
Origins

Upper two thirds of anterior surface of femur

Insertions

Upper border of patella and patellar tendon to tibial tuberosity

Vastus Medialis



Actions

Extends the knee

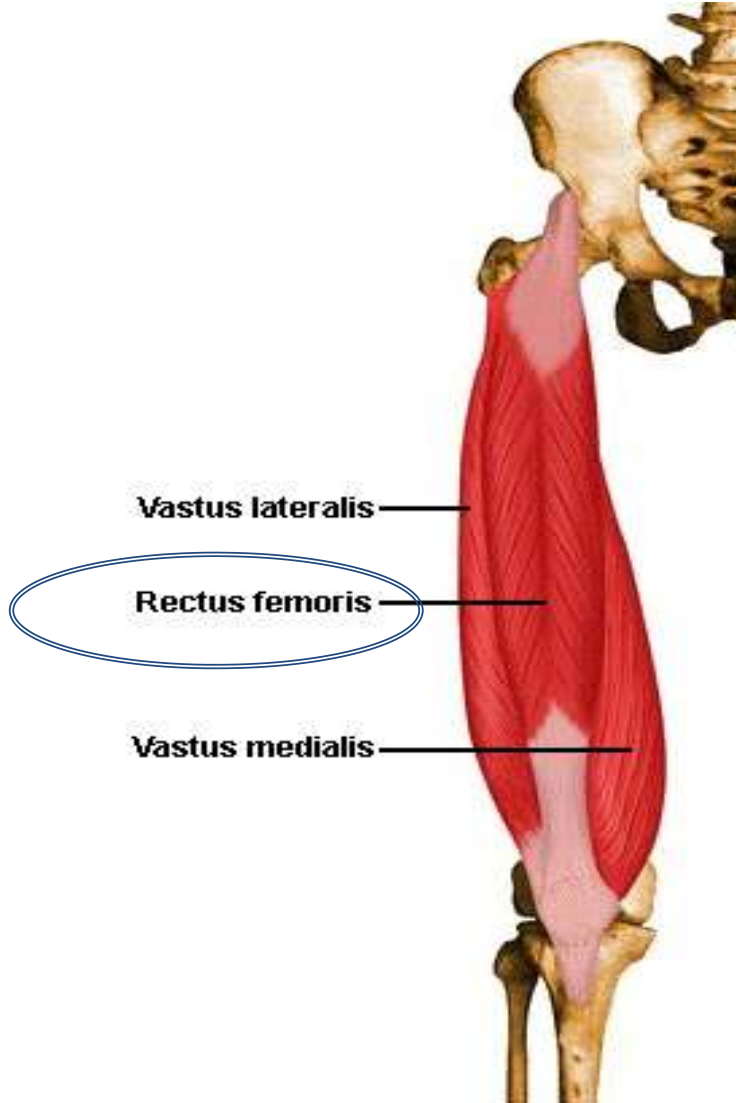
Origins

Whole length of linea aspera and medial condyloid ridge

Insertions

Medial half of upper border of patella and patellar tendon to tibial tuberosity

Rectus Femoris



Actions

Extends the knee, flexes the hip

Origins

Anterior inferior iliac spine of the ilium and superior margin of acetabulum

Insertions

Superior aspect of patella and patellar tendon to tibial tuberosity