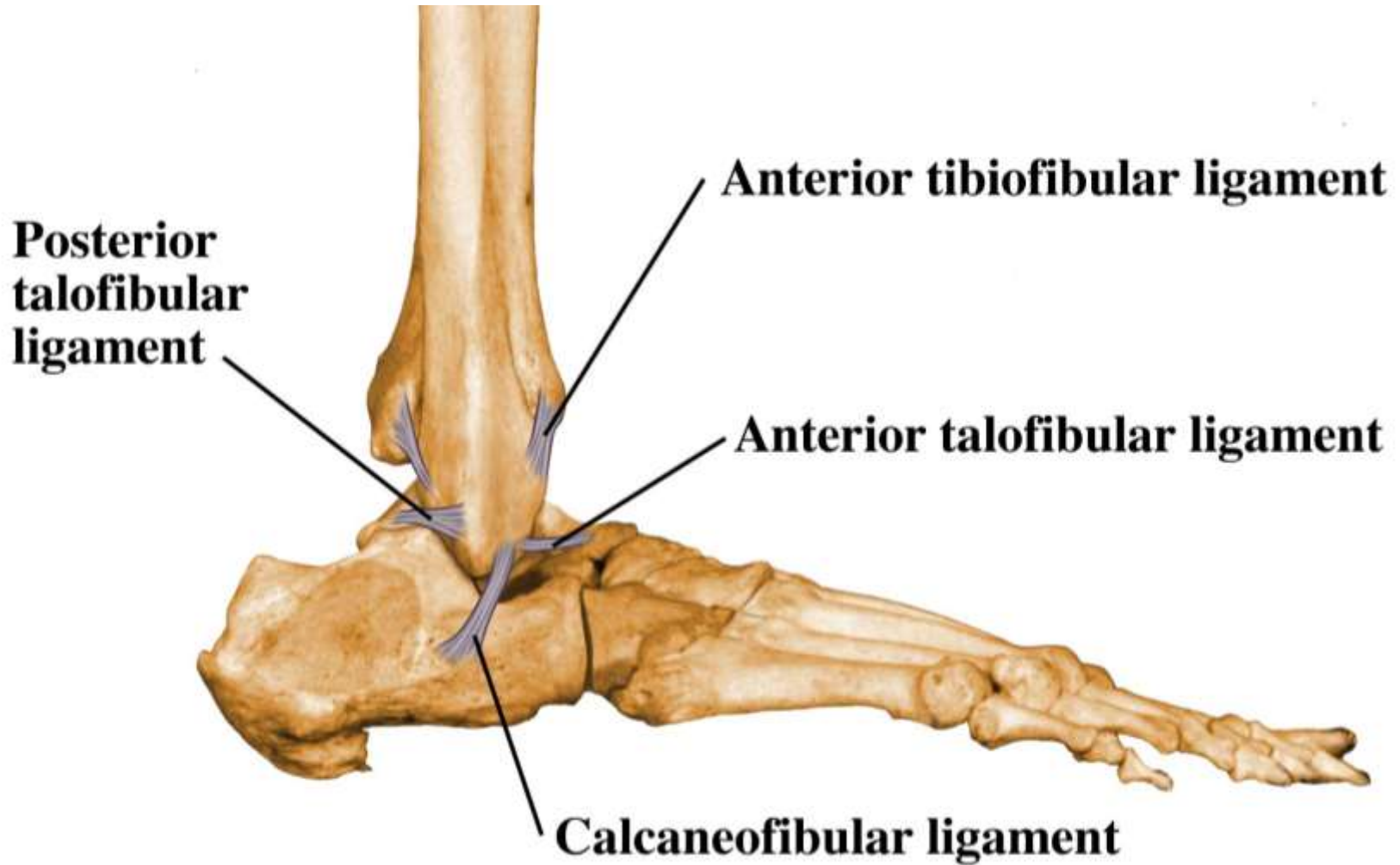


Lower Leg & Ankle

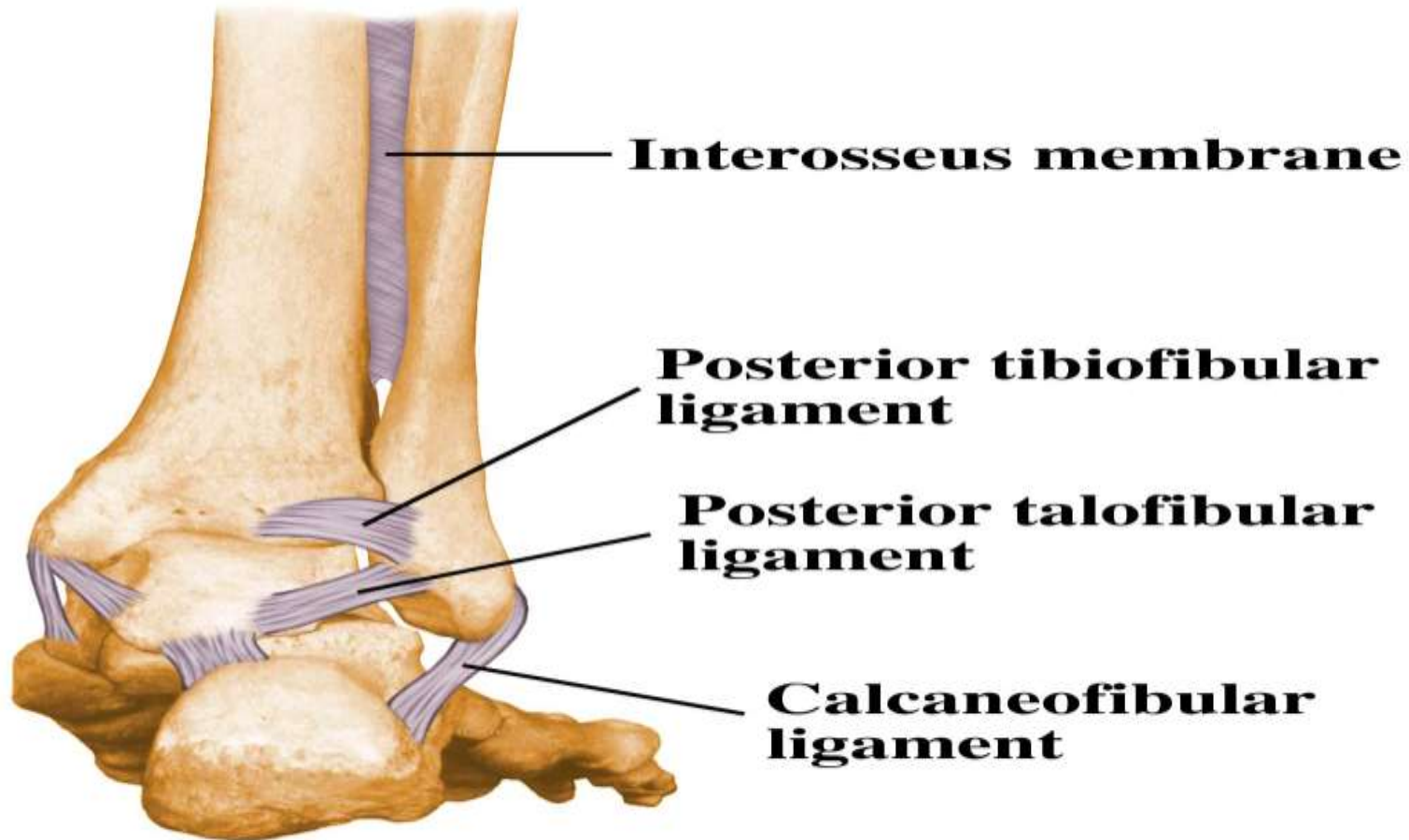


Joint

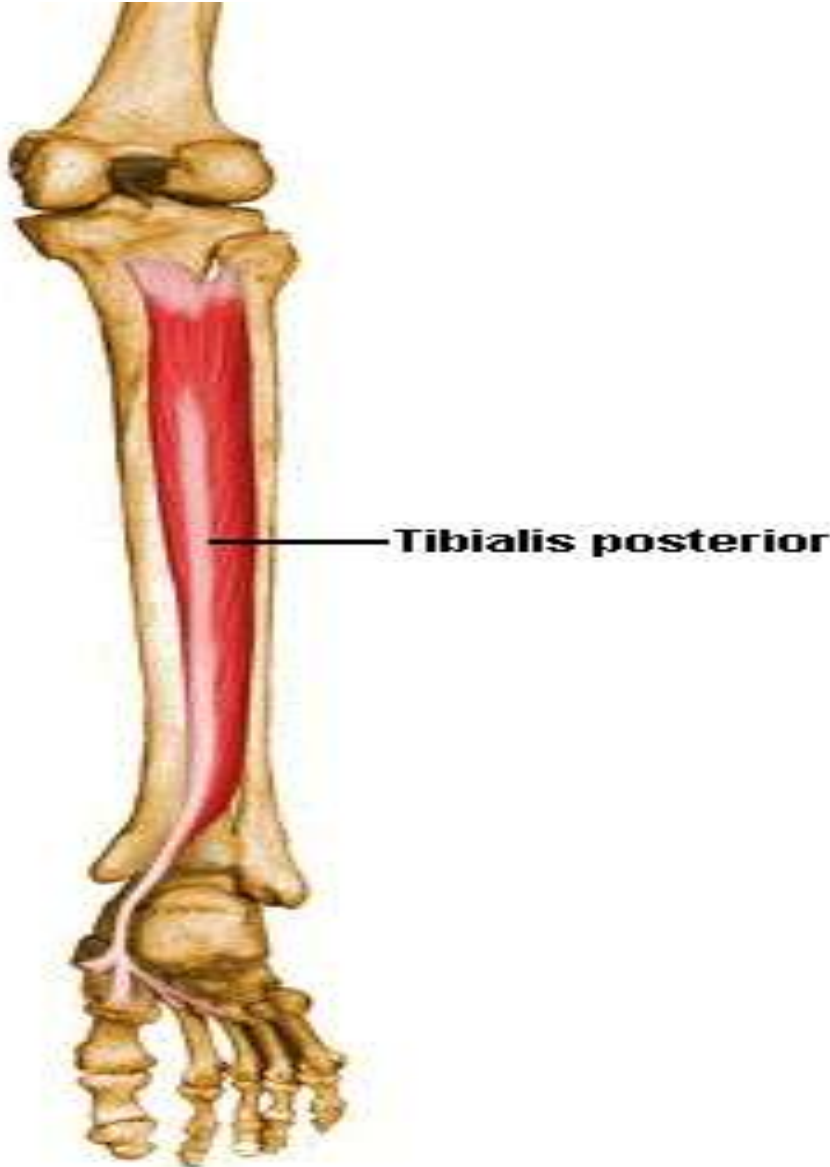




Joint



Posterior Tibialis



Actions

Plantarflexes and inverts the foot

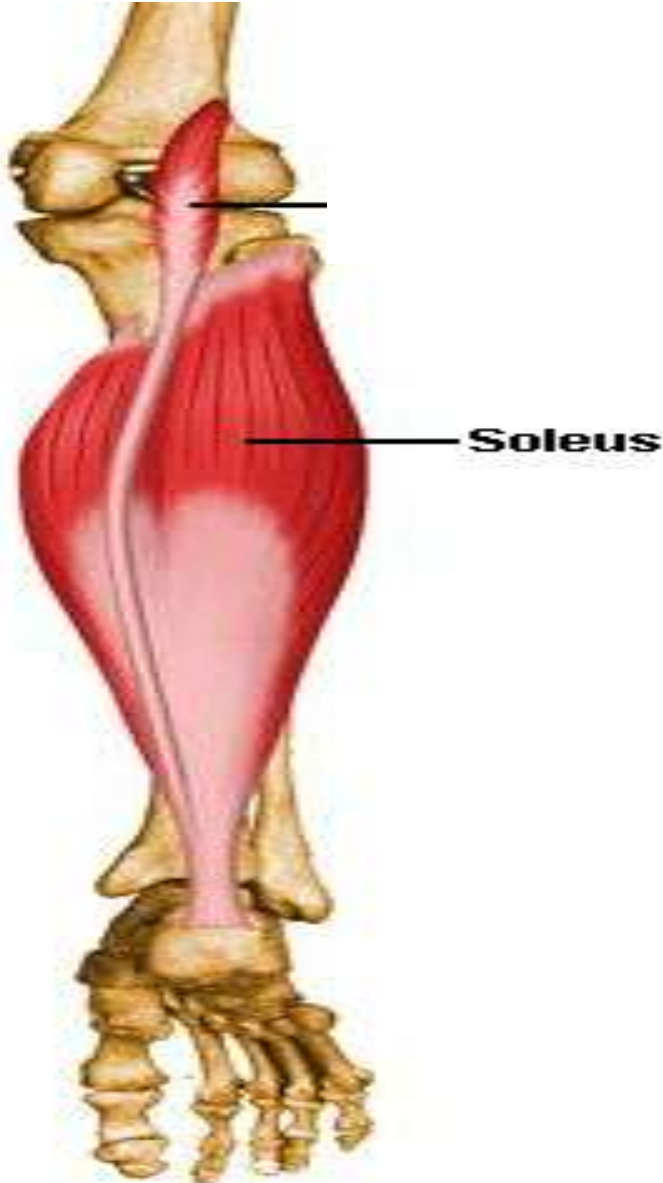
Origins

Posterior surface of upper half of interosseous membrane and adjacent surfaces of the tibia and fibula

Insertions

Lower inner surfaces of navicular bones and bases of the second to fifth metatarsal bones

Soleus



Actions

Plantarflexes the foot

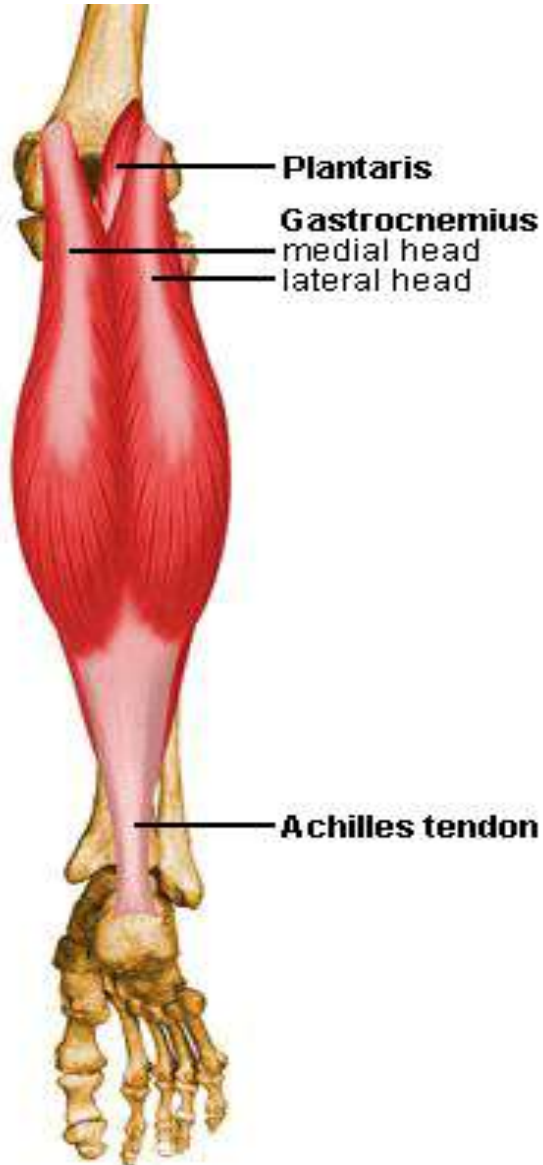
Origins

Posterior surface of proximal fibula and proximal tibial surface

Insertions

Posterior surface of the calcaneus (Achilles tendon)

Gastrocnemius



Actions

Plantarflexes the foot; flexes the knee

Origins

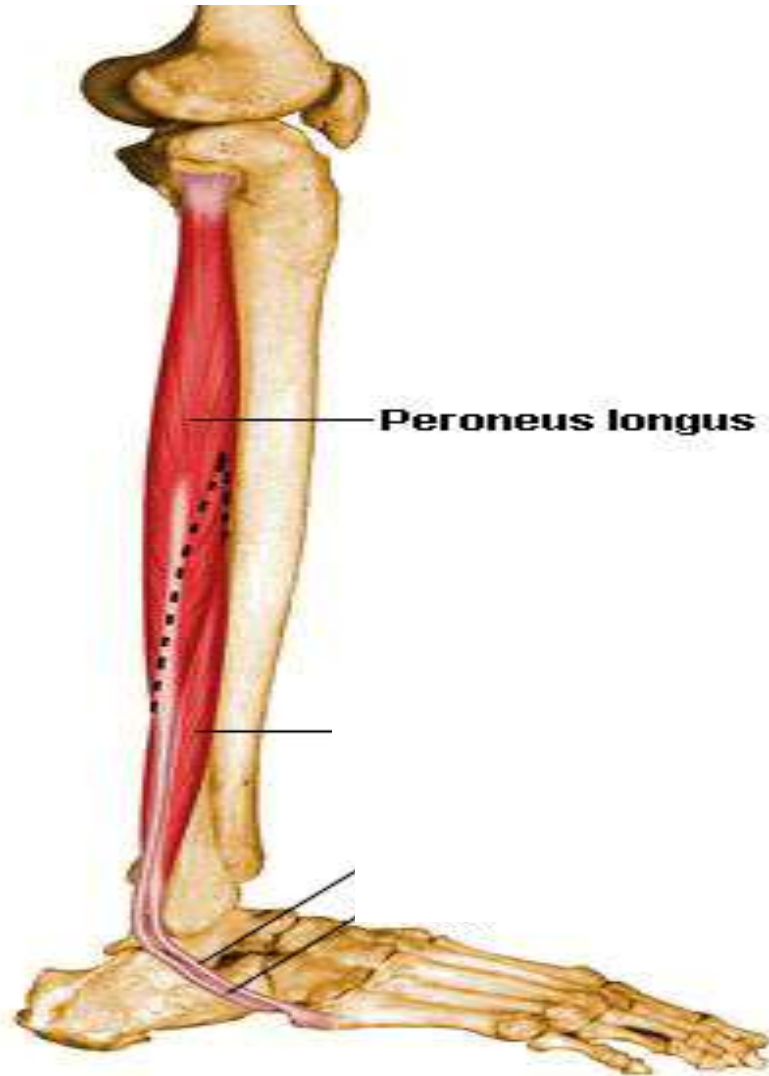
Medial head: posterior surface of medial femoral condyle

Lateral head: posterior surface of the lateral femoral condyle

Insertions

Posterior surface of the calcaneus (Achilles tendon)

Peroneus Longus



Actions

Everts and plantar flexes the ankle

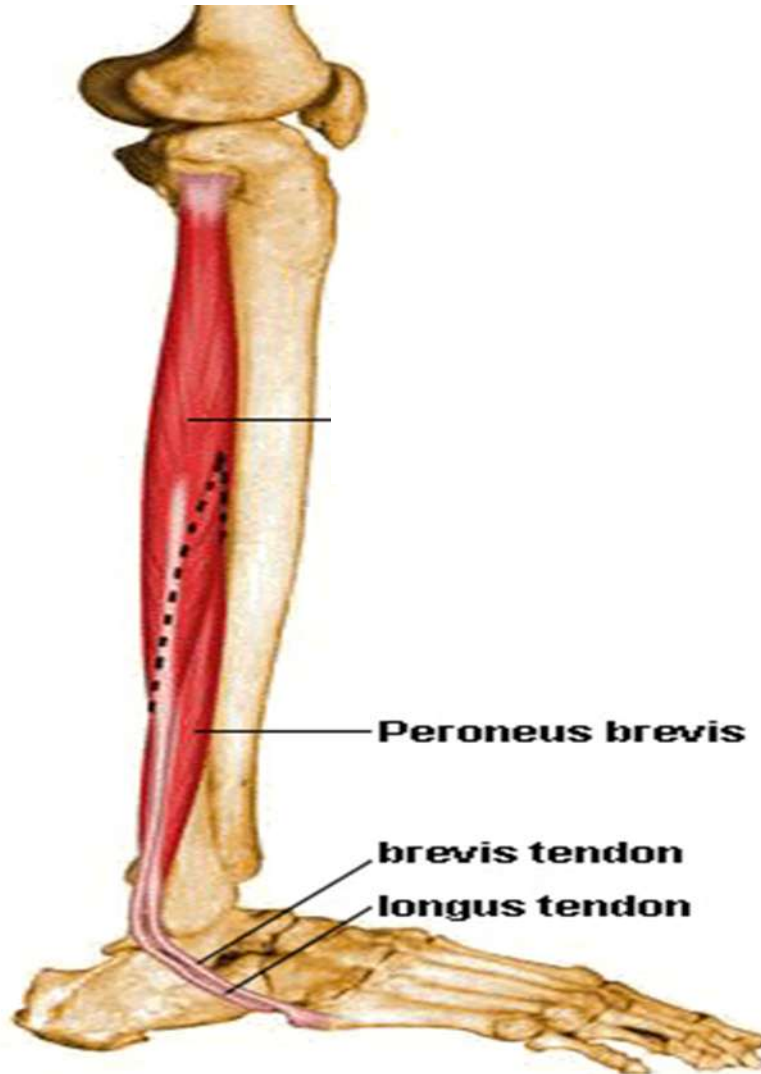
Origins

Head and upper two thirds of lateral surface of the tibia

Insertions

Under surfaces of the cuneiform and first metatarsal

Peroneus Brevis



Actions

Everts and plantar flexes the ankle

Origins

Lower two thirds of lateral surface of tibia

Insertions

Tuberosity of the fifth metatarsal bone

Peroneus Tertius

Actions

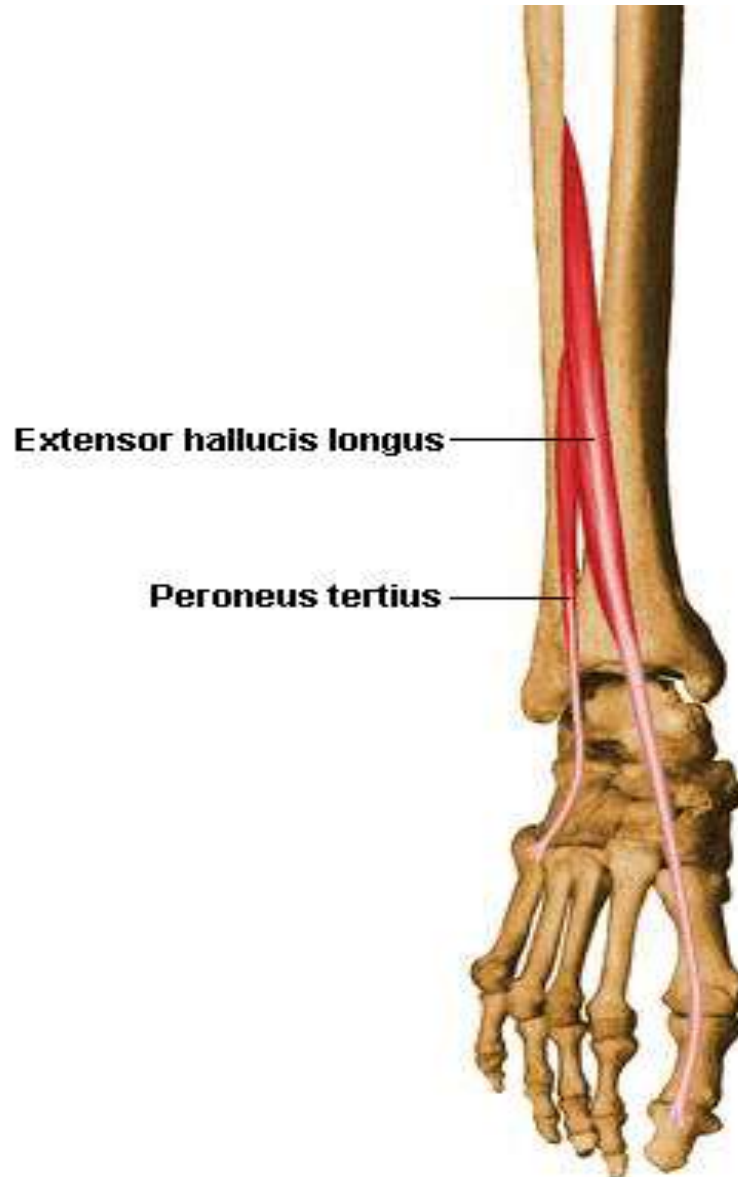Everts and dorsiflexes the ankle

Origins

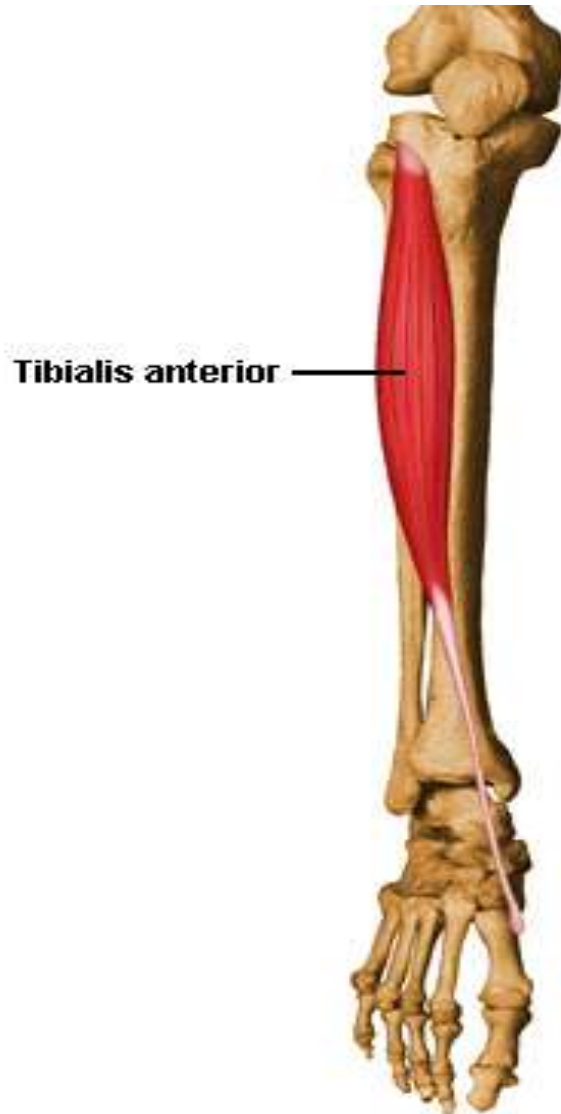Distal third of anterior fibula

Insertions

Base of the fifth metatarsal



Tibialis Anterior



Actions

Dorsiflexes and inverts the foot

Origins

Upper two thirds of lateral surface of tibia

Insertions

Inner surface of medial cuneiform and first metatarsal